

Er-Xian Decoction, a traditional Chinese herbal formula, intervening early in hypothalamic-pituitary axis of male rats with delayed puberty

Zheng Zhu, LiHong Li, Xin Jin, JianWei Fang, DongFang Zhang

Department of Pharmacognosy, School of Pharmacy, China Medical University, Shenyang, PR China

Submitted: 18-10-2013

Revised: 04-11-2013

Published: 26-09-2014

ABSTRACT

Background: Er-Xian Decoction (EXD) is one of the traditional Chinese medicine (TCM) with unique effect on osteoporosis, menopausal syndrome and delayed puberty in China for many years. **Objective:** We aim to evaluate the potential activity of starting hypothalamic-pituitary-testicular (HPT) axis of male rats with delayed puberty. **Materials and Methods:** Delayed puberty model of male Sprague-Dawley (SD) rats were established with soy isoflavones (90 mg·kg⁻¹) and were treated by EXD extract at doses of 5, 10 g·kg⁻¹ or Testosterone undecanoate (TU) for 8 weeks. Body weight, body length, testis weight, T, E₂ and luteinizing hormone (LH) in serum, gonadotropin releasing hormone (GnRH) in hypothalamus, follicle stimulating hormone (FSH) and LH in pituitary gland were determined by ELISA. Immunohistochemistry was used to detect LH in pituitary gland. **Results:** Soy isoflavones could significantly decrease body weight, body length, testicular organ coefficient T in serum, GnRH in hypothalamus, FSH and LH in pituitary gland. Both of EXD and TU could improve the condition. E₂ and LH in serum of all groups were non-significance of difference ($P > 0.05$). The immunohistochemical results were well consistent with LH in pituitary gland. **Conclusion:** The results of the present research indicate that EXD extract is effective to start the HPT axis in puberty and can significantly improve sexual developmental inhibition caused by soy isoflavones.

Key words: Delayed puberty, Er-Xian Decoction, traditional Chinese medicine

INTRODUCTION

Puberty is described as delayed puberty with exceptions when an organism has passed the usual age of onset of puberty with no physical or hormonal signs that it is beginning. It occurs mainly in boys. Delayed puberty is a chronic disease induced by hypernutrition,^[1] hypomotility, environment estrogen, etc., Puberty is a specific period for sexual development of male. Delayed puberty can induce poor sexual development and it is an important reason of sterility in males,^[2,3] and it has been an urgent social question. The disease should be timely treated in puberty for its particularity.

Many exogenous compounds from process of human production and life *in vivo*, analog or antagonize physiological role of natural hormones, were released into environment and existed for a long time. These exogenous compounds could directly or indirectly be accumulated and they can

bond with hormone receptor, which led to nervous system disorders, endocrine disorders, weakened immune system and reproductive abnormalities, developmental toxicity, embryo toxicity, developing cancer and immunosuppressive diseases. Once the substances, named as endocrine secretion interferential, enter into organism, it can interfere endocrine secretion system and take effect on exist and reproductive. Delayed puberty caused by exposure to environmental estrogens such as cadmium, mercury, bisphenol A (BPA) and dioxin. In boys, exposure to PCBs, PCDFs or the pesticide endosulfan was associated with delayed puberty or decreased penile length.^[4] The fungicide vinclozolin (V) was found to inhibit sexual differentiation in male rats in an antiandrogenic manner.^[5] Food is also a main source of exposure to endocrine active compounds, many of which have been linked to adverse health effects. Phytoestrogens, especially from soy are the major dietary source of estrogenicity. Soy and soy-derived products contain isoflavones that mimic the actions of estrogens and may exert adverse effects on male fertility.^[6]

Er-Xian Decoction (EXD), a nontraditional Chinese medicine formula in the early 1950s, is composed of

Access this article online

Website:

www.phcog.com

DOI:

10.4103/0973-1296.141780

Quick Response Code:



Address for correspondence:

Prof. DongFang Zhang, No. 92 Bei'er Road, Heping District, Shenyang City - 110 001, PR China.
E-mail: lnsyzdf@sohu.com

six herbs including *Herba Epimedii* (Yinyanghuo), *Radix morindae Officinalis* (Bajitian), *Radix Angelicae Sinensis* (Danggui), *Rhizoma Anemarrhenae* (Zhimu), *Cortex Phellodendri* (Huangbo) and *Rhizoma Curculiginis* (Xianmao). EXD was designed and named by Zhang Bo-na, a professor at the Shanghai University of Traditional Chinese Medicine in China.^[7] The formula with unique effect on nourishing both of kidney-yang and kidney-yin and has been used to treat osteoporosis^[8,9] female menopausal syndrome,^[10] male climacteric syndrome^[11] and delayed puberty in China for many years. In this research, we aim at to evaluate the potential activity of triggering hypothalamic–pituitary–testicular (HPT) axis of male mouse in puberty and accelerating sexual development.

MATERIALS AND METHODS

Chemicals and plant materials

Testosterone undecanoate (TU) were purchased from Zhejiang medicine Co., LTD Xinchang Pharmaceutical Factory (Zhejiang, China).

Soy isoflavones, *Herba Epimedii*, *Radix morindae Officinalis*, *Radix Angelicae Sinensis*, *Rhizoma Anemarrhenae*, *Cortex Phellodendri* and *Rhizoma Curculiginis* were purchased from Supply and Marketing Company, Northeast Pharmaceutical Group Co., LTD (Shenyang, China).

Preparation of the EXD extract and HPLC analyses

Six dry crude herbs stated in the prescription were mixed, then ground into powder and boiled in distilled water (100g/800 mL, 1.5h × 2). The filtrate was dried under reduced pressure, ground and the resulting powder was used. The yield of extraction was 28% (g/g). Icariin and berberine in extract were determined by high performance liquid chromatography (HPLC). The content of icariin and berberine was respective 0.81% and 1.34%.

Grouping of animals and model

Sixty three-week-old male Sprague–Dawley (SD) rats were supplied by the Experimental Animal Centre, China Medical University (SYXK (Liao) 2003-0013). The animals were housed in an air-conditioned room at an ambient temperature of 24° and 50-65% relative humidity with automatic 12-h light: 12-h dark cycles. 60 rats were randomly chosen and subdivided into 6 groups (each 10 rats): Normal control group (NC), soy isoflavones group (SI-90 mg · kg⁻¹), soy isoflavones and testosterone undecanoate (SI-90 mg · kg⁻¹+TU-10 mg · kg⁻¹), SI-90 mg · kg⁻¹+EXD-10g · kg⁻¹, SI-90 mg · kg⁻¹ and EXD-5 g · kg⁻¹ and NC+EXD-5 g · kg⁻¹ group. The rats in NC group and NC+EXD-5 g · kg⁻¹ group were orally

administered with water and the rest rats were orally administered with soy isoflavones (90 mg · kg⁻¹). After three weeks, The EXD dry powder or TU was dissolved in water and orally administered to the rats for 8 weeks. All animals received humane care during the study with unlimited access to chow and water.

Sampling harvesting

When treated for 8 weeks, the body weight and body length of all rats were measured. The rats were anesthetized with 40 mg/kg sodium pentobarbital. Blood sample was collected from abdominal aorta and then centrifuged at 3000 r/min × 30 min, the serum was kept at -70°. The testes specimens were immediately collected dried by filter paper and weighted in the wet state and then testicular organ coefficient (testis weight (g)/body weight (100 g)) was calculated. The testes specimens were fixed in 10% phosphate-buffered formalin. The rats were inflicted into death. hypothalamus and hypophysis were collected and snap-frozen in liquid nitrogen and then the tissues were stored at -70°C.

Testis histological analysis

Formalin-fixed testis tissue was processed in 5µm thick paraffin sections, which were stained with hematoxylin and eosin (HE). The tissue sections were subjected to microscopic examination.

Biochemical analysis

The concentrations of T, E₂ and luteinizing hormone (LH) in serum, gonadotropin releasing hormone (GnRH) in hypothalamus, follicle stimulating hormone (FSH) and LH in pituitary gland were determined by enzyme linked im-munosorbent assay (ELISA) and the test kits were purchased from Adlitteram Diagnostic Laboratories, Ins., USA.

Immunohistochemical analysis

Immunohistochemistry was used to detect LH in pituitary gland. The test kits were purchased from Adlitteram Diagnostic Laboratories, Ins., USA. The experimental results were examined under a microscope.

Statistical analysis

All results were expressed as mean ± SE. The data were analyzed by using one-way analysis of variance (ANOVA) followed by Student's *t*-test using SPSS computer software version 16.0, Level of significance was fixed at 0.05.

RESULTS

Effect of EXD extract on body weight and body length

Soy isoflavones could suppress body development of rats. Compared with the normal group, body weight and body

length of were significantly decreased in the SI-90mg·kg⁻¹ group, ($P < 0.05$). EXD extract and TU could accelerate body development. Body weight and body length of the EXD groups and the TU group were significantly higher than those of SI-90mg·kg⁻¹ group ($P < 0.05$). EXD could increase body weight of normal rats and had no obvious effect on body length from the results between the NC and NC+EXD groups [Table 1].

Effect of the EXD extract on testicular organ coefficient

Soy isoflavones could restrain testicular development. Testes weight and testicular organ coefficient of the soy isoflavones model rats were significantly lower than those of the control group ($P < 0.05$), however, the EXD extract and TU can enhance Testes weight significantly, when compared with that of the model group, ($P < 0.05$) and made them reach normal level, when compared with that of the control group. ($P > 0.05$). The NC+EXD-5 g·kg⁻¹ rats were non-significance of difference when compared with the NC group. ($P > 0.05$) [Table 1].

Effect of EXD extract on serum biochemical parameters

Testosterone secret was suppressed by soy isoflavones. Testosterone of the SI model group was significantly lower than that of control group ($P < 0.05$). EXD extract and TU could enhance level of testosterone and made it reach normal level, compared with that of the control group. ($P > 0.05$) and compared with that of SI model group. ($P < 0.05$) EXD could promote the secretion of T of the normal rats. E₂ and LH of all groups were non-significance of difference ($P > 0.05$) [Table 2].

Effect of the EXD extract on biochemical parameters in hypothalamus and pituitary gland

Compared with normal rats, GnRH were significantly decreased in SI normal group. As an exogenous estrogen, soy isoflavones negative feed back to inhibit secretion of GnRH through the hypothalamic - pituitary axis. EXD could improve the levels of GnRH and made it reach normal levels, but TU had no work. FSH and LH in pituitary gland were significantly decreased in SI model group when compared with normal rats. EXD could enhance the levels of FSH and LH. TU had roles in the secretion of FSH and LH, but the latter was insignificant [Table 3].

Testes histological examination

Testis seminiferous tubules of the control rats were developed normally. Spermatogenic cells were arranged tightly and the structures of the cells were clear. Spermatogium, primary spermatocyte and spermatid in tubule could be all examined. Seminiferous tubule had been fully developed [Figure 1a]. Spermatogenic cell loss and tubular atrophy accompanied by modifications in

Table 1: Effect of the EXD extract on body weight, body length and testicular organ coefficient in rats ($\bar{x} \pm s$, $n=10$)

Groups	Body weight (g)	Body length (cm)	Testicular organ coefficient (g/100 g)
NC	236.1±14.4	21.0±0.8	0.69±0.17
SI-90 mg·kg ⁻¹	216.3±10.3 ^a	19.8±0.9 ^a	0.66±0.03 ^a
SI-90 mg·kg ⁻¹ +TU-10 mg·kg ⁻¹	242.3±35.6 ^a	21.0±0.7 ^b	0.68±0.04 ^b
SI-90 mg·kg ⁻¹ +EXD-10 g·kg ⁻¹	241.4±14.5 ^b	21.0±0.8 ^b	0.68±0.02 ^b
SI-90 mg·kg ⁻¹ +EXD-5 g·kg ⁻¹	240.5±20.6 ^b	20.6±0.6 ^b	0.67±0.11 ^b
NC+EXD-5 g·kg ⁻¹	242.0±12.8 ^{ab}	20.7±1.0 ^b	0.69±0.03 ^b

All values are expressed as mean±SE, ^a $P < 0.05$, when compared with the control rats, ^b $P < 0.05$, when compared with the model rats, EXD: Er-Xian Decoction; NC: Normal control group; TU: Testosterone undecanoate

Table 2: Effect of the EXD extract on serum biochemical parameters ($\bar{x} \pm s$, $n=10$)

Groups	T (ng/dl)	E ₂ (pg/ml)	LH(ng/dl)
NC	11.64±1.78	19.78±1.41	10.25±1.61
SI-90 mg·kg ⁻¹	10.35±1.32 ^a	19.27±1.49	10.91±1.28
SI-90 mg·kg ⁻¹ +TU-10 mg·kg ⁻¹	12.03±2.00 ^b	19.34±1.64	10.29±2.03
SI-90 mg·kg ⁻¹ +EXD-10 g·kg ⁻¹	12.42±2.07 ^b	19.19±1.41	10.27±2.08
SI-90 mg·kg ⁻¹ +EXD-5 g·kg ⁻¹	12.12±1.06 ^b	19.29±2.18	10.30±0.55
NC+EXD-5 g·kg ⁻¹	14.01±1.48 ^{ab}	19.22±1.42	10.25±1.07

All values are expressed as mean±SE, ^a $P < 0.05$, when compared with control rats, ^b $P < 0.05$, when compared with high-fat model rats, EXD: Er-Xian Decoction; NC: Normal control group; TU: Testosterone undecanoate

Table 3: Effect of the EXD extract on GnRH in hypothalamus and FSH and LH in pituitary gland ($\bar{x} \pm s$, $n=10$)

Groups	Hypothalamus	Pituitary gland	
	GnRH (pg/ml)	FSH (mIU/ml)	LH (ng/dl)
NC	11.72±1.45	12.21±1.30	9.78±1.17
SI-90 mg·kg ⁻¹	10.62±1.15 ^a	10.38±0.80 ^a	9.35±1.81 ^a
SI-90 mg·kg ⁻¹ +TU-10 mg·kg ⁻¹	10.39±0.54 ^a	11.65±1.29 ^b	9.83±1.57
SI-90 mg·kg ⁻¹ +EXD-10 g·kg ⁻¹	11.48±1.63 ^b	11.43±1.04 ^b	10.29±0.88 ^b
SI-90 mg·kg ⁻¹ +EXD-5 g·kg ⁻¹	11.42±1.43 ^b	11.88±1.40 ^b	10.16±2.12 ^b
NC+EXD-5 g·kg ⁻¹	11.73±0.86 ^b	11.35±0.95 ^a	10.17±1.20 ^b

All values are expressed as mean±SE, ^a $P < 0.05$, when compared with control rats, ^b $P < 0.05$, when compared with high-fat model rats, EXD: Er-Xian Decoction; GnRH: gonadotropin releasing hormone; FSH: Follicle stimulating hormone; LH: luteinizing hormone; NC: Normal control group; TU: Testosterone undecanoate

seminiferous epithelium composition and morphology were observed in the SI rats. Cells falling off could be observed and individual spermatogenic cells separated from basement membrane and the clustered cells fallen in the seminiferous tubule [Figure 1b]. Seminiferous tubule of the EXD groups and the TU group was the same as that of control group [Figures 1c-f]. EXD treatment could make testis seminiferous tubule develop normally.

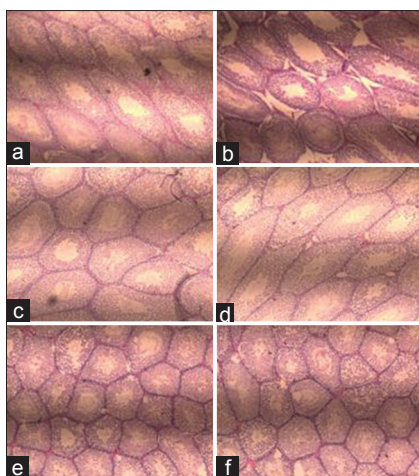


Figure 1: The photomicrograph of testis seminiferous tubules. (a) control; (b) SI-90 mg·kg⁻¹ (model); (c) SI-90 mg·kg⁻¹+TU-10 mg·kg⁻¹; (d) SI-90 mg·kg⁻¹+ EXD-10 g·kg⁻¹; (e) SI-90 mg·kg⁻¹ and EXD-5 g·kg⁻¹; (f) NC+EXD-5 g·kg⁻¹. Testis seminiferous tubules of the SI-90 mg·kg⁻¹ (model) rats were developed abnormally, the others were developed normally

Immunohistochemical analysis

Through immunohistochemical analysis of LH in pituitary gland, the results were well consistent with biochemical parameters of LH in pituitary gland [Figure 2].

CONCLUSION AND DISCUSSION

The puberty of male rat is from 6th week to 10th week.^[12] Three-week-old male rats in prepuberty were fed with soy isoflavones. The EXD extract was fed in six-week-old. The rats were treated and put to death at 14th weekend (treated for 8 weeks), when the rats were in adult. Body weight, body length can reflect body growth condition. The concentrations of T, E₂ and LH in serum, GnRH in hypothalamus, FSH and LH in pituitary gland can reflect hypothalamus- pituitary axis function. Testes weight and testis organ coefficient can reflect sexual development condition. The results show that the EXD extract can enhance T, GnRH and LH. It can trigger the HPT axis. Body weight, body length, testes weight and testis organ coefficient data are just the results of start-up of the HPT axis.

That the HPT axis is triggered timely is important to growth and development of male children in puberty. The results of experiment show that the soy can suppress start-up of the HPT axis and the EXD extract can improve the inhibition action of soy. GnRH and LH of the soy model rats is significantly lower than that of control rats. It expresses that soy can suppress the release of GnRH and LH in hypothalamus or hypophysis and suppress the run-up of the HPT axis. GnRH and LH of The EXD extract rats is significantly higher than that of the soy model rats and

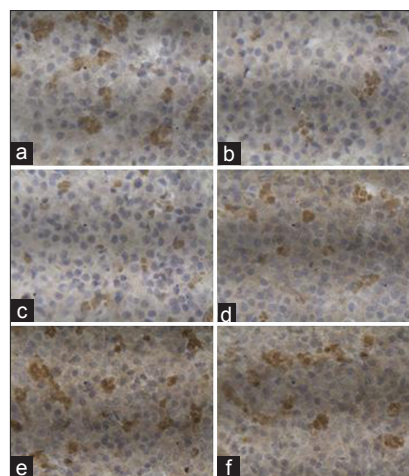


Figure 2: Immunohistochemical analysis of LH in pituitary gland. (a) control; (b) SI-90 mg·kg⁻¹ (model); (c) SI-90 mg·kg⁻¹+TU-10 mg·kg⁻¹; (d) SI-90 mg·kg⁻¹+ EXD-10 g·kg⁻¹; (e) SI-90 mg·kg⁻¹ and EXD-5 g·kg⁻¹; (f) NC+EXD-5 g·kg⁻¹. The results were well consistent with the biochemical parameters in pituitary gland

the same as that of the control rats. It expresses that the EXD extract can elevate the express levels of GnRH and LH and startup the axis. Testosterone of the soy model rats was significantly lower than that of control rats, while, The EXD extract can enhance level of testosterone and facilitate sexual development and accelerate body growth and testis development.

Start-up of puberty is also start-up of the hypothalamic-pituitary-testicular (HPT) axis. Hyperadiposity can suppress the HPT axis and delay development of testis and produce of sperm. Clinical and pharmacological researches express that many hormones are correlated with functions of the HPT axis and influence directly and indirectly sexual development in puberty, especially, GnRH, LH and testosterone play very important roles in pubertal development of male.

Soy isoflavones are phytoestrogens with potential hormonal activity due to their similar chemical structure to 17-β-estradiol.^[13] Pediatricians and parents recommend suspending all possible estrogen-contaminated food, especially meat (poultry, beef) and soy products, when the child presents with a pubertal disorder.^[14]

Drugs for delayed puberty include testosterone undecanoate, testosterone intramuscular and oxandrolone.^[15] Natural testosterone and its esters rarely produce side-effects, but exogenous testosterone suppresses the production of LH and FSH and leads to reduced testicular sperm production and, consequently, reduced testicular volume. Androgen is considered normal in adult and is inappropriate in childhood.^[16] This results show that TU has effect on start-up of puberty, but not on start-up of the HPT axis.

Er-Xian Decotion, A traditional Chinese herbal formula, is advantageous.

The results of the present research indicate that EXD extract is effective to start the HPT axis in puberty and can significantly improve the inhibition of the growth and development of rats caused by soy isoflavones. The results provide experimental evidence in treating male delayed puberty. It is highly possible to develop EXD extract as a drug to intervene early in pubertal development.

ACKNOWLEDGMENT

This work was supported by the Natural Science Foundation of Liaoning Province (No. 2012010155-401).

REFERENCES

1. Wang Y, Liu X, Qin D, Chen S, Li Y. Diet-induced obesity affects testis development in pubertal rats. *Nat J Androl* 2007;13:514-9.
2. Hammoud AO, Gibson M, Peterson CM, Meikle AW, Carrell DT. Impact of male obesity on infertility: A critical review of the current literature. *Fertil Steril* 2008;90:897-904.
3. Pauli EM, Legro RS, Demers LM, Kunselman AR, Dodson WC, Lee PA. Diminished paternity and gonadal function with increasing obesity in men. *Fertil Steril* 2008;90:346-51.
4. Den Hond E, Schoeters G. Endocrine disruptors and human puberty. *Int J Androl* 2006;29:264-71.
5. Gray LE, Ostby JS, Kelce WR. Developmental Effects of an Environmental Antiandrogen: The Fungicide Vinclozolin Alters Sex Differentiation of the Male Rat. *Toxicol Appl Pharm* 1994;129:46-52.
6. Cederroth CR, Auger J, Zimmermann C, Eustache F, Nef S. Soy, phyto-oestrogens and male reproductive function: A review. *Int J Androl* 2010;33:304-16.
7. Zhong LL, Tong Y, Tang GW, Zhang ZJ, Choi WK, Cheng KL, *et al.* A randomized, double-blind, controlled trial of a Chinese herbal formula (Er-Xian decoction) for menopausal symptoms in Hong Kong perimenopausal women. *Menopause* 2013;20:767-76.
8. Nian H, Qin LP, Zhang QY, Zheng HC, Yu Y, Huang BK. Antiosteoporotic activity of Er-Xian Decotion, a traditional Chinese herbal formula, in ovariectomized rat. *J Ethnopharmacol* 2006;108:96-102.
9. Qin LP, Han T, Zhang QY, Cao DP, Nian H, Rahman K, *et al.* Antiosteoporotic chemical constituents from Er-Xian Decotion, a traditional Chinese herbal formula. *J Ethnopharmacol* 2008;118:271-9.
10. Liu Q, Shi JR, Yang Y, Fang ZQ, Liang SH, Guo RX. Effects on secretory function of rat gonad by Er-Xian Decotion and its disassembled prescriptions. *China J Chin Mater Med* 2005;30:1023-6.
11. Yang M, Ren D, Chen J, Lu Y, Zeng X. Clinical research of Er Xian Soup on the treatment of the male climacteric syndrome. *Chin J Androl* 2007;27:46-8.
12. Korenbrot CC, Huhtaniemi IT, Weiner RI. Preputial separation as an external sign of pubertal development in the male rat. *Biol Reprod* 1977;17:298-303.
13. Dinsdale EC, Ward WE. Early Exposure to Soy Isoflavones and effects on reproductive health: A review of human and animal studies. *Nutrients* 2010;2:1156-87.
14. Alves C, Flores LC, Cerqueira TS, Toralles MB. Environmental exposure to endocrine disruptors with estrogenic activity and the association with pubertal disorders in children. *Rep Public Health* 2007;23:1005-14.
15. Mushtaq T, Wales JK. Diagnosis, investigation and treatment of delayed puberty in children. *Pediatr Child Health* 2007;17:349-55.
16. Rolf C, Nieschlag E. Potential adverse effects of long-term testosterone therapy. *Baillieres Clin Endocrinol Metab* 1998;12:521-34.

Cite this article as: Zhu Z, Li L, Jin X, Fang J, Zhang D. Er-Xian Decotion, a traditional Chinese herbal formula, intervening early in hypothalamic-pituitary axis of male rats with delayed puberty. *Phcog Mag* 2014;10:517-21.

Source of Support: Nil, **Conflict of Interest:** None declared.