

Euphorbia hirta accelerates fibroblast proliferation and Smad-mediated collagen production in rat excision wound

Aadesh Upadhyay^{1,2}, Pronobesh Chattopadhyay¹, Danswring Goyary¹, Papiya M. Mazumder², Vijay Veer¹

¹Division of Pharmaceutical Technology, Defence Research Laboratory, DRDO, Tezpur, Assam, ²Department of Pharmaceutical Sciences, Birla Institute of Technology, Mesra, Ranchi, Jharkhand, India

Submitted: 12-07-2013

Revised: 26-08-2013

Published: ****

ABSTRACT

Background: *Euphorbia hirta* L. (Euphorbiaceae) is a traditional herbal medicine used for treatment of various diseases. **Objective:** *E. hirta* was investigated for *in vitro/in vivo* wound healing activity using human dermal fibroblast cell line and Wistar rats. **Materials and Methods:** Petroleum ether, chloroform, methanol and water successive extracts of *E. hirta* leaves were evaluated for antioxidant, antimicrobial and fibroblast proliferation activities. Among different extracts, the promising methanol extract was screened for wound healing activity in Wistar rats, using gentamicin sulfate (0.01% w/w) as a reference. Wound contraction, hydroxyproline content and the protein expression of COL3A1, bFGF, Smad-2,-3,-4 and -7 were measured. **Results:** The *E. hirta* methanol extract showed a potent antimicrobial (MIC 0.250 mg/ml against *Escherichia coli* and *Klebsiella pneumoniae*, both), antioxidant activities (IC₅₀ = 10.57 µg/ml 2,2-diphenyl-1-picrylhydrazyl; 850.23 µg/ml superoxide-anion radical scavenging activity and 23.63 mg gallic acid equivalent per gram extract) with significant fibroblast proliferating activity (112% at 12.5 µg/ml) as compared to other extracts. *In vivo* study also supported the wound healing potential of methanol extract, as evidenced by faster wound contraction, higher hydroxyproline (4.240 mg/100 mg tissue) and improved histopathology of granulation tissue as compared to control groups and gentamicin sulfate-treated ones. Western blot also revealed a significantly altered expression of Smad-mediated proteins resulting in collagen production. **Conclusion:** The study suggested that *E. hirta* accelerates the wound healing by augmenting the fibroblast proliferation and Smad-mediated collagen production in wound tissue.

Key words: Basic fibroblast growth factor, *Euphorbia hirta*, hydroxyproline, smad-mediated collagen production, wound healing

INTRODUCTION

Euphorbia hirta L. is an annual herb of Euphorbiaceae family, and a widely used traditional medicine in tropical countries. The plant is reported to use for asthma, cough, bronchitis, pulmonary disorders, diarrhea, dysentery, vomiting, fever, oral thrush, boils, sores, athlete's foot and burns.^[1,2] *E. hirta* has also been reported for hepatoprotective, diuretic, analgesic-antipyretic and anti-inflammatory, anticancer, antimalarial, antiplasmodial, antidiabetic and antimicrobial activities.^[1,2] The plant is reported to contain polyphenolics such as euphorbin-A, euphorbin-B, euphorbin-C,

euphorbin-E.^[3] Quercitrin, myricitrin, rutin, kaempferol, quercetin, gallic acid and protocatechuic acid are among the other major phenolic derivative. *E. hirta* contains β-amyrin, 24-methylenecycloartenol, β-sitosterol, heptacosane, nonacosane, shikimic acid, camphol and quercitol derivatives containing rhamnose.^[1,2]

Cutaneous wound is a disruption of cellular, anatomical and functional continuity of skin tissue and healing is a natural tissue restorative process. From ancient times plant-based medicines have been used in wound management and many scientific documents highlighted the plant medicine-induced alteration of wound healing phases such as coagulation, inflammation, proliferation of fibroblast, collagen formation, re-epithelialization and wound remodeling.^[4,5] In this context, the aim of the present study was to investigate the wound healing

Access this article online

Website:

www.phcog.com

DOI:

10.4103/0973-1296.139801

Quick Response Code:



Address for correspondence:

Dr. Pronobesh Chattopadhyay, Division of Pharmaceutical Technology, Defence Research Laboratory, DRDO, Tezpur, Assam – 784 001, India.
E-mail: chattopadhyay.drl@gmail.com

activity and related properties (antimicrobial and antioxidant properties) of *E. hirta* with specific reference to fibroblast-proliferating activity and Smad-mediated collagen production in Wistar rat.

MATERIALS AND METHODS

Reagents

Mueller-Hinton broth, gallic acid, 2, 2-diphenyl-1-picrylhydrazyl (DPPH) and nitroblue tetrazolium chloride (NBT) were purchased from Sigma. The Folin Ciocalteu's reagent (FCR), phenazine methosulfate (PMS), nicotinamide adenine dinucleotide, reduced (NADH), potassium ferrocyanide, trichloroacetic acid (TCA), ferric chloride and hydrogen peroxide were procured from Himedia. All the solvents and chemical not mentioned were of analytical grade.

Cell line

Human dermal fibroblast (106-05) was purchased from Sigma-Aldrich and cultured in Dulbecco's modified eagles' medium (DMEM) containing 10% fetal bovine serum and antibiotics (100 U/ml penicillin and 100 U/ml streptomycin) in a humidified CO₂ incubator with 5% CO₂ at 37°C. The media was replaced every alternate day and the cells were harvested on confluency, using 0.05% trypsin-EDTA and sub-cultured in a fresh medium.

Bacteria

The bacterial strains *Bacillus subtilis* (MTCC 441), *Staphylococcus aureus* (MTCC 3160), *Streptococcus mutans* (MTCC 890), *Escherichia coli* (MTCC 443), *Klebsiella pneumoniae* (MTCC 109) and *Pseudomonas aeruginosa* (MTCC 741) were obtained from Institute of Microbial Technology (IMTECH), Chandigarh, India.

Plant collection and extraction

E. hirta leaves were collected between September and November (2011) from the herbal garden of Defence Research Laboratory, Tezpur, Assam, (India) and authenticated from Botanical Survey of India, Shillong, Assam (India) and the specimen sample was deposited (Accession number 85248). About 100 g shade dried leaf powder was packed into a steel thimble (28 × 100 mm) with diatomaceous earth and sequentially extracted with petroleum ether, chloroform, methanol and water at 1500 lb at room temperature in accelerated solvent extractor (ASE 1.5, Dionex, USA). The extraction was considered complete when the initial color of the percolate gradually changed to colorless. The solvents were evaporated using a rotatory evaporator (Rotavac, Heidolph 2, Schwabach, Germany) at 45 ± 2°C for organic extracts and freeze-dried for the

aqueous extract; the yield of extracts were calculated and stored at 4°C until further analysis.

Antimicrobial and antioxidant assay

Agar broth dilution technique was used for the determination of minimum inhibitory concentration (MIC) according to the method of Hayouni *et al.*^[6] using 62-2000 µg/ml of extracts.

DPPH free radical and superoxide anion radical scavenging activity (SRSA) were performed as described earlier.^[7,8] Total phenolic content and ferric ion reducing-antioxidant power assay (FRAP) were estimated using the modified procedure of Wang and Dai^[9] at 10-1000 µg/ml extract concentrations.

Fibroblast proliferation assay

The fibroblast proliferation assay was performed as described by Adetutu *et al.*^[10] Confluent human dermal fibroblasts were trypsinized, centrifuged and re-suspended in DMEM supplemented with 10% FBS, 100 µg/ml streptomycin, 100 U/ml penicillin and 2.5 µg/ml fungizone. Cells (1000 cells/well) were seeded per well in 96-well plate excluding first row and maintained at 37°C in humidified 5% CO₂ atmosphere. The medium was replaced after 24 h of incubation with DMEM containing 0.5% FBS and extract samples. The final concentration for each extract ranged from 1.56 to 100 µg/ml. DMEM/0.5% FBS and DMEM/10% FBS serve as normal and growth stimulation control. The cells were incubated for 48 h, and before 2 h of culture termination, 20 µl of resazurin solution (100 µg/ml) was added. Absorbance was measured at 570 nm using a SpectraMax Plus 384 micro-plate reader (Molecular Devices, USA). Each sample was assayed in triplicate and three independent tests were performed.

Hydrogen peroxide-induced oxidative stress

Hydrogen peroxide (0.1 mM) was used to induce oxidative stress as described by Adetutu *et al.*^[10] Human dermal fibroblasts (106-05) were seeded 5 × 10³ cells per well (10% FBS/DMEM) in 96-well plate, incubated at 37°C in a humidified 5% CO₂ incubator. After 24 h, the media was replaced with fresh DMEM containing different concentrations of extracts (1.56-100 µg/ml) and simultaneously exposed to 0.1 mM hydrogen peroxide for 3 h at 37°C. Catalase (250 U/ml) was used as positive control. After the incubation, cell viability was assessed as described above. Each sample was assayed in triplicate and three independent tests were performed.

Wound healing activity

Animals

Healthy adult male Wistar rats (250-300 g) and Swiss albino mice (20-25 g) housed at Defence Research Laboratory,

Tezpur (Assam, India) were acclimatized for 3 days. Animals were maintained on a standard pellet diet and water *ad libitum* throughout the experiment. Ethical approval was obtained from Defence Research Laboratory Animals Ethical Committee (IAEC/DRL/05/July/2011).

Acute skin irritation and toxicity study

The acute skin irritation and toxicity study was performed for therapeutic dose of *E. hirta* methanol extract according to the OECD guidelines-402 (OECD guidelines, 1987). Hydrogel of methanol extract 1% and 2.5% (w/w) prepared in Carbopol 934 containing 5% propylene glycol were applied on the shaved portion, back of the mice and monitored for 14 days for an abnormal skin response including irritation, redness itching, inflammation and other related symptoms.^[11]

Wound creation and treatment

Circular 20 mm diameter wounds were caused on depilated dorsal skin of anesthetized Wistar rat. The animals were randomly segregated into four groups ($n = 20$): Group 1: non-treated control; Group 2: vehicle control; Group 3: 2.5% (w/w) *E. hirta* methanol extract and Group 4: 0.01% (w/w) gentamicin sulfate. All samples including gentamicin sulfate were prepared in hydrogel base containing 0.5% Carbopol-934 and 5% propylene glycol. Treatments were given once daily until complete epithelialization. One third of the animals were euthanized on day-7 post injury and wound granulation tissues (excluding any underlying muscle and extraneous tissue) were harvested. A portion of harvested tissue was immediately stored in liquid nitrogen for further analysis and another portion was fixed in 4% formaldehyde for histopathological study. Half of the remaining animals were euthanized on day-15 post injury; the entire granulation tissue was used for histopathological assessment. Remaining animals were observed until complete epithelialization.

Wound contraction measurement

The progressive changes of wounded area were photographed (Nikon Coolpix-S3000 camera) at 3 day interval from day 0, until complete epithelialization. All wound images were evaluated by using special size ImageJ analysis software (National Institutes of Health, Maryland, USA). The changes in the wound size were expressed as percentage contraction of the original wound size (day 0).

Estimation of hydroxyproline content

Hydroxyproline content was analyzed on 7 day post injury granulation tissue as described earlier.^[11] The hydrolyzed samples of wound tissue (30 mg) were mixed with 1 ml of 0.01 M CuSO_4 followed by the addition of 1 ml of 2.5 N

NaOH and then 1 ml of 6% H_2O_2 . The solution was mixed and shaken occasionally for 5 minutes. All the tubes were incubated at 80°C for 5 min with frequent vigorous shaking. Upon cooling, 4 ml of 3 N H_2SO_4 was added with agitation. Finally, 2 ml of 5% *p*-dimethyl-amino-benzaldehyde was added and incubated at 70°C for 15 min, cooled by placing the tubes in water at 20°C. Absorbance was measured at 500 nm using a UV-VIS spectrophotometer (CE7200, Cecil Instruments Ltd, Cambridge, USA). The standard calibration curve was plotted for pure hydroxyproline and used for estimation of the test samples.

Histopathological studies

The harvested wound tissues were sectioned (6 μm thick) perpendicular to the wound and stained with hematoxylin-eosin (HandE) and Masson's trichrome (MT) stains. Tissues were examined by a light microscope for epithelialization, inflammatory cell infiltration, fibroblast proliferation, neovascularization and collagen deposition.

Western blotting

The harvested wound tissues were homogenized in a lysis buffer containing 50 mM Tris-HCl (pH 7.4), 150 mM NaCl in tissue homogenizer (MM 400, Retsch, Newtown, USA). The equal amount of protein was electrophoresed on the 12% SDS-PAGE with 4% stacking gel at 80 V for 45 min; thereafter, proteins were transblotted onto the PVDF membrane. The membranes were incubated overnight with COL3A1, bFGF, Smad-2, -3, -4, -7 and β -actin primary antibodies (1:1000) followed by 4 h incubation with secondary antibodies (1:2000) on rocking shaker (Rockymax, Tarsons, Kolkata, India). The desired proteins were detected by Western Max-HRP-Chromogenic detection kit and BCIP-NBT solution (Amresco, Solon Ind. Pkwy., Ohio, USA).

Statistical analysis

The results were expressed as mean \pm S.D. Data were statistically analyzed using one-way analysis of variance (ANOVA) followed by the Dunnett test. A $P \leq 0.05$ was considered statistically significant as compared to the non-treated and vehicle-treated groups.

RESULTS

Extracts' yield and screening of phytochemical

The powdered *E. hirta* leaf sample (100 g) yield 3.07 g petroleum ether extract (EhPE), 1.85 g chloroform extract (EhCE), 17.86 g methanol extract (EhME) and 11.39 g water extract (EhWE). The preliminary phytochemical screening showed the presence of alkaloid, flavonoids, terpenes, phenolic and carbohydrates in different extracts (Supplementary 1).^[12]

Antimicrobial and antioxidant activities

Tables 1, 2 and Figure 1 summarized the antimicrobial and antioxidant (DPPH, SRSA, FCR and FRAP) activity of *E. hirta* extracts. In the antimicrobial assay, methanol

Table 1: Antibacterial activity of different *E. hirta* leaves extracts expressed as minimum inhibitory concentration in mg/ml

Bacteria	MIC (mg/ml)			
	EhPE	EhCE	EhME	EhWE
<i>Bacillus subtilis</i>	>2	1	0.5	2
<i>Staphylococcus aureus</i>	0.5	2	1	>2
<i>Streptococcus mutant</i>	>2	1	2	2
<i>Escherichia coli</i>	>2	>1	0.25	>2
<i>Klebsiella pneumoniae</i>	2	>2	0.25	>2
<i>Pseudomonas aeruginosa</i>	2	1	2	>2

EhPE: *E. hirta* petroleum ether extract; EhCE: *E. hirta* chloroform extract; EhME: *E. hirta* methanol extract; EhWE: *E. hirta* water extract; Chloramphenicol was used as positive control (MICs < 90 µg/ml). MIC: Minimum inhibitory concentration

Table 2: Scavenging activity of different *E. hirta* extracts against DPPH and superoxide radicals and their Folin-cioalteau reagent reducing capacity

<i>Euphorbia hirta</i> L.	Scavenging activity against DPPH radical (IC ₅₀ ± S.D.)	Scavenging activity against superoxide radical (IC ₅₀ ± S.D.)	FCR reducing capacity (mg _{GAC} /g _{extract})
EhPE	NA	NA	0.14 ± 0.01
EhCE	NA	NA	7.11 ± 0.65
EhME	10.57 ± 1.49	850.23 ± 33.14	23.63 ± 0.27
EhWE	18.74 ± 2.38	489.75 ± 4.22	16.21 ± 0.44
Gallic acid	1.10 ± 0.39	156.86 ± 36.39	-

IC₅₀ values are expressed in µg/ml; NA: Not active; S.D.: Standard deviation; IC₅₀: Amount of antioxidant necessary to scavenge the initial DPPH/superoxide radical by 50%; mg_{GAC}/g_{extract}: mg of gallic acid equivalent/gram of extract; GAC: Gallic acid; EhPE: *E. hirta* petroleum ether extract; EhCE: *E. hirta* chloroform extract; EhME: *E. hirta* methanol extract; EhWE: *E. hirta* water extract; FCR: Folin-cioalteau reagent; DPPH: Diphenyl-1-picrylhydrazyl

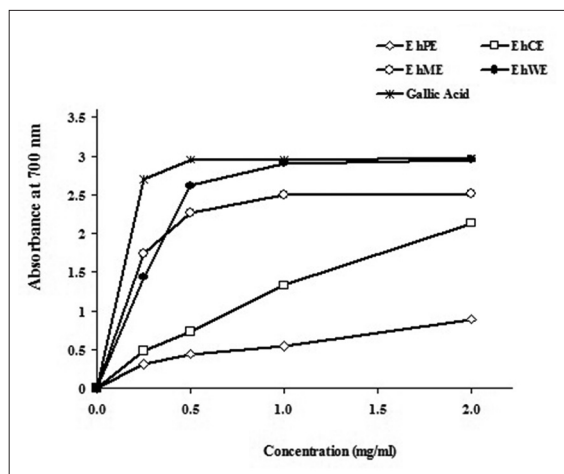


Figure 1: Ferric ion reducing antioxidant power (FRAP) of different *E. hirta* extracts

extract was found to be very active (MIC 0.25-2 mg/ml) as compared to other solvent extracts, the gram-negative *E. coli* and gram-negative *K. pneumoniae* were found to be the most sensitive with MIC 0.25 mg/ml, both [Table 1]. For chloroform extract MIC values were ranging between 1 and 2 mg/ml. Petroleum ether and water extracts were poor in antimicrobial activity against selected pathogens.

In antioxidant evaluations, EhPE and EhCE were found inactive against DPPH and superoxide radical scavenging activity and showed 0.14 and 7.11 mg gallic acid equivalents, respectively in the FCR assay [Table 2]. EhME and EhWE were potent antioxidant extracts, in which EhME showed higher DPPH radical scavenging activity in comparison to EhWE with IC₅₀ (µg/ml) values 10.57 and 18.74, respectively. Whereas, EhWE (IC₅₀ = 489.75 µg/ml) possess higher superoxide radical scavenging strength in comparison to EhME (IC₅₀ = 850.23 µg/ml). FRAP and FCR assay data further revealed the antioxidant potency of EhME and EhWE [Figure 1, Table 2].

Fibroblast proliferation

Fibroblast proliferation assay showed that EhPE and EhCE decreased the cell population from 98% to 68% and 99% to 73%, respectively with increasing concentrations (1.56-100 µg/ml). However, the cell survival was more

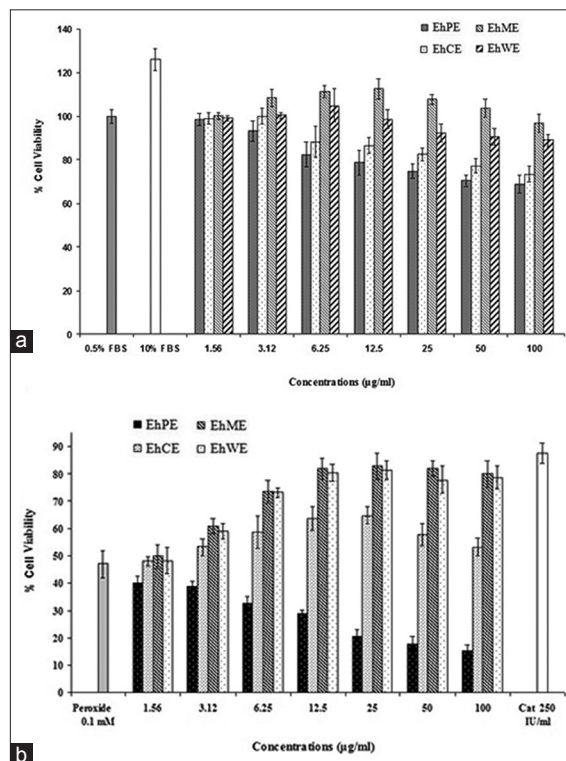


Figure 2: (a) Effect of *E. hirta* extracts on human dermal fibroblast proliferation. (b) Protection of human dermal fibroblast cells against hydrogen peroxide-induced damage with simultaneous application of different *E. hirta* extracts. Values are expressed as mean ± SD

than 80% up to 25 $\mu\text{g/ml}$ concentrations [Figure 2a]. On the other hand, EhME showed the biphasic response as the fibroblast population increased from 100% to 112% (1.56-12.5 $\mu\text{g/ml}$) and decreased from 112% to 96% with higher concentrations (12.5-100 $\mu\text{g/ml}$). Similarly, EhWE showed an initial elevation of cell population, however gradually decreased from 105% to 89% (6.25 to 100 $\mu\text{g/ml}$) [Figure 2a].

Hydrogen peroxide induced oxidative stress

As shown in Figure 2b, hydrogen peroxide (1.0×10^{-4} M) exposure for 3 h resulted in the decrease of cell population up to 46.93%. The EhPE did not show any protection against oxidative cell damage, moreover decreased the cell count with increasing concentration (1.56-100 $\mu\text{g/ml}$). The EhCE has shown increase in cell population from 47% to 53% (1.56-100 $\mu\text{g/ml}$). On the other hand, EhME and EhWE showed a dose-dependent protection as the cell population increased from 49% to 80% and 48% to 78%, respectively (1.56 to 100 $\mu\text{g/ml}$). Both, EhME and EhWE (12.5 $\mu\text{g/ml}$) showed almost the same level of protection as in catalase (250 U/ml).

Wound healing

Acute skin irritation and toxicity

In the skin irritation and toxicity study, tested hydrogel concentrations did not show any symptoms of irritation and inflammation, therefore high concentration of 2.5% (w/w) hydrogel was selected for the *in vivo* wound healing study.

Wound contraction rate

Figure 3a gives a pictorial representation of wound healing in different treatment groups. Wound contraction was expressed as percentage compared to wound size on day zero (100%) for non-treated, vehicle, EhME and gentamicin sulfate-treated groups [Figure 3b]. The EhME-treated animal group showed 58.82%, 74.39%, 84.05% and 93.73% wound contraction, whereas gentamicin sulfate-treated group showed 48.22%, 59.61%, 75.05% and 82.56% wound contraction in 9, 12, 15 and 18 post-operative days, respectively. On the other hand, non-treated animal group showed 15.69%, 23.29%, 29.07% and 42.29% wound contraction and vehicle-treated group showed 28.44%, 36.94%, 44.27% and 52.50% wound contraction, respectively. The contraction rate was significantly higher ($P < 0.05$) in the EhME-treated group as compared to the non-treated and vehicle-treated control group.

Hydroxyproline content

Hydroxyproline content in EhME and gentamicin sulfate-treated groups were observed significantly higher ($P < 0.05$) as compared to non-treated and vehicle-treated ones [Figure 3c]. Besides, hydroxyproline content of the EhME-treated group also showed higher level ($P < 0.05$) as compared to the gentamicin sulfate-treated group.

Histopathological evaluations

Histopathological examination of the wound granulation tissue indicated the accelerated wound healing processes

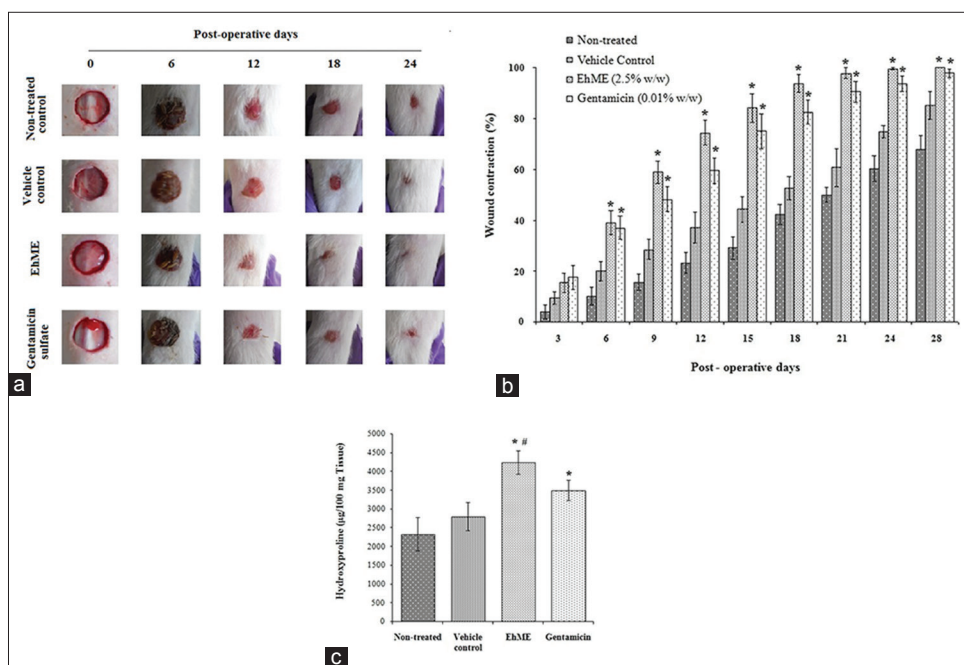


Figure 3: Effect of *E. hirta* methanol extract (EhME) on wound healing. (a) Pictorial representation of wound closure in Wistar rat; (b) Wound contraction rate. (c) Hydroxyproline content. Values are expressed as mean \pm SD. Asterisk (*) indicates significantly different ($P < 0.05$) as compared to the non-treated and vehicle-treated groups

with high mononuclear cells infiltration and fibroblasts proliferation, and rapid remodeling in the EhME-treated animal group. The epithelialization rate was slow with lesser collagen bundles formed in vehicle and non-treated groups [Table 3]. EhME-treated wound tissue

showed (7 days) less inflammatory cell with increased infiltration of mononuclear/fibroblast cells [Figure 4]. Ulcer and edematous areas were absent in both EhME and gentamicin sulfate treatments. Histopathology on day 15 precisely delineated the EhME-accelerated wound healing and showed well-organized re-epithelialization with abundant fibroblast density, compact collagen layering and faster keratinization with intraepithelial cornification. Few matured hair follicles were observed in thick matured dermis [Figure 4]. Masson's trichrome staining showed a clear and distinct collagen layering with high macrophage and fibroblast density in the EhME-treated group. On the other hand, gentamicin treatment showed complete re-epithelialization with a few irregular packing of collagen fibers and minor to moderate macrophage infiltration [Figure 4]. In vehicle and non-treated animal groups, collagen bundles were loosely packed and granulation tissue was moderately cellular with mononuclear and fibroblast cells.

Table 3: Histopathological evaluation of wound healing process in different treatment groups

Groups	Wound healing process								
	S	U	Ed	PMC	MNC	FP	RE	CD	NV
Day 7									
Non-treated	++	++	++	+++	+	+	+	-	+/-
Vehicle control	++	+	++	+++	+	+	+	-/+	+
EhME (2.5%)	+	-	-	+	+++	+++	++	++	++
Gentamicin sulfate (0.01%)	+	-	-	++	++	++	+	+/-	++
Day 15									
Non-treated	+	+	-/+	+	++	++	+	++	++
Vehicle control	+	+	-	+	++	++	+	++	++
EhME (2.5%)	-	-	-	-	-/+	+++	+++	+++	++
Gentamicin sulfate (0.01%)	-	-	-	-/+	+	++	++	++	++

HE and MT staining were scored as mild (+), moderate (++) and severe (+++) for epidermal and/or dermal re-modeling. S: Scab; U: Ulcer; Ed: Edema; PMC: Polymorphonuclear cells; MNC: Mononuclear cells; FP: Fibroblast proliferation; NV: Neovascularization; CD: Collagen deposition; RE: Re-epithelialization; EhME: *E. hirta* methanol extract

Effect of *E. hirta* on Smad-mediated collagen production in wound granulation tissue

Western blot analysis showed a significantly increased ($P < 0.05$) expression of COL3A1 and bFGF protein in

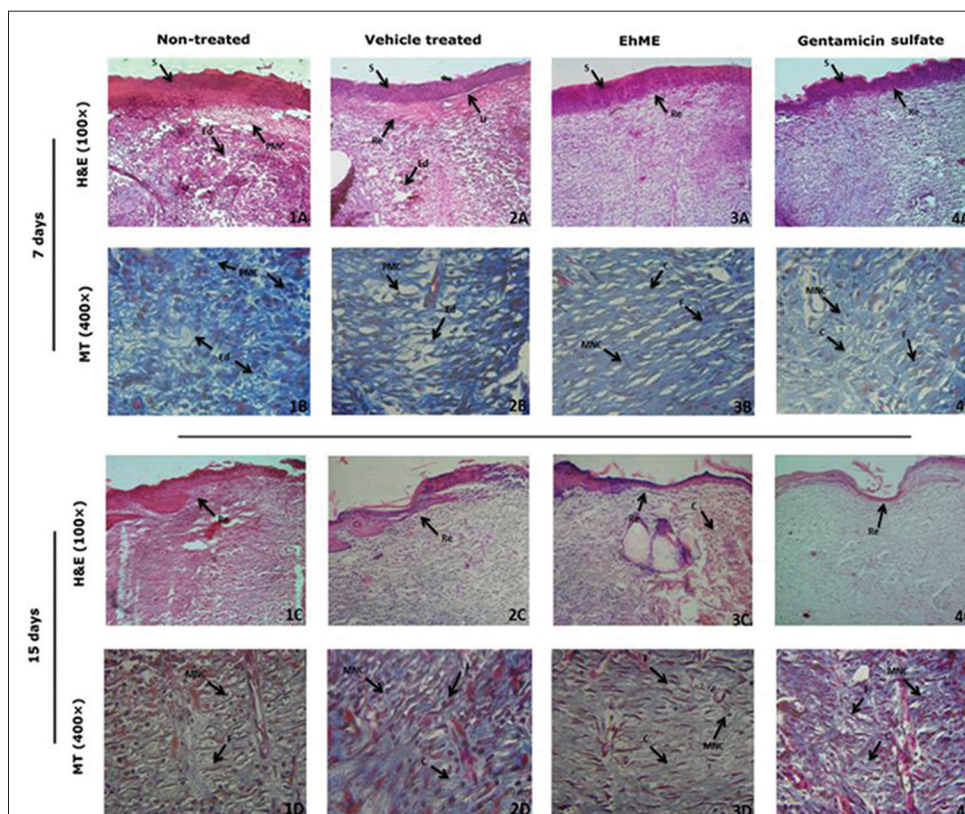


Figure 4: Microscopic view of healing wound granulation tissue and re-modeling epidermis/dermis in (1) non-treated, (2) vehicle control, (3) EhME and (4) gentamicin sulfate-treated animal groups. Section shows the hematoxylin and eosin (HandE) stained epidermis and dermis in A, C (100 x), and Masson's trichrome (MT) stained dermis in B, D (400 x) of 7- and 15-days post operative treated animal groups, respectively. Arrow pointing the events of wound healing- S: Scab; U-Ulcer; Re: Re-epithelialization; F: Fibroblast; PMC: Polymorphonuclear cells; MNC: Mononuclear cells; C: Collagen; and NV: Neovascularization

EhME and gentamicin sulfate-treated wound granulation tissue [Figure 5]. Seven days EhME treatment increased the expression level of signal transducer protein Smad-2, -3 and -4, and down regulated the inhibitory protein Smad-7 as compared to non-treated and vehicle-treated groups. However, the magnitude of expression of proteins (COL3A1, bFGF and Smad-2, -3 and -4) were significantly higher ($P < 0.05$) in EhME as compared to gentamicin sulfate. The β -actin was used as an internal control.

DISCUSSION

Cutaneous wound healing is a complex cascade of tissue regeneration and restoration involving different phases of inflammation, proliferation and remodeling. The uprising tools of scientific investigations had proven the wound healing potential of plant medicines.^[4,5,13] The phytochemical and pharmacological investigations revealed the ethnobotanical importance of *E. hirta* for various ailments^[1,2] and the present study has also supported by exploring the wound healing properties.

The successive extraction of *E. hirta* leaves was performed to attain the desirable active therapeutic

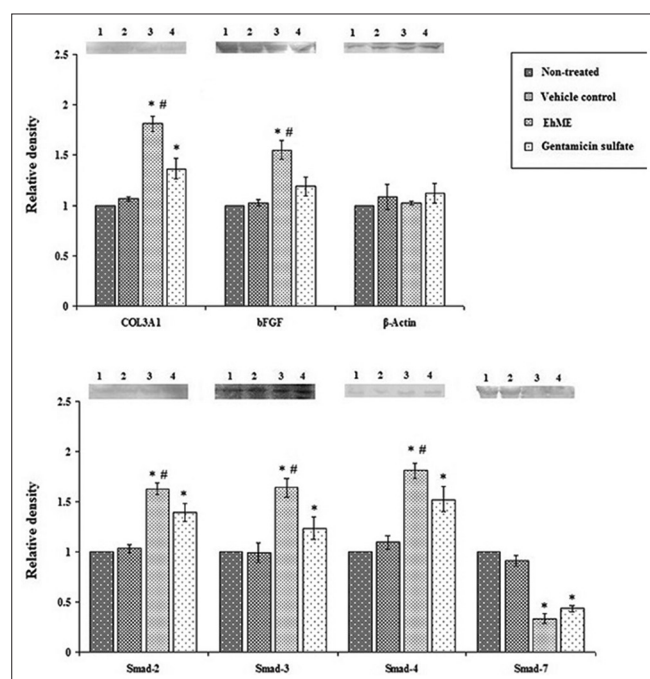


Figure 5: Effect of *E. hirta* methanol extract (EhME) on COL3A1, bFGF Smad-2, 3, 4 and 7 protein expressions on day 7 (seven) in wound tissues, detected by western blot. Lane (1) non-treated, (2) vehicle control, (3) EhME and (4) gentamicin sulfate-treated animal group, respectively. Values are expressed as mean \pm SD. Asterisk (*) indicates significantly different ($P < 0.05$) as compared to the non-treated and vehicle-treated groups. Hash (#) indicates significantly different ($P < 0.05$) as compared to the gentamicin sulfate-treated group

wound healer extract and to eliminate the non-active component, as the *E. hirta* has been reported to possess the anticancer properties i.e. certain phyto-constituent have anti-proliferative and/or apoptosis-inducing potential.^[1] The open cutaneous wound provides a favorable environment for microbial growth. The bacteria such as *B. subtilis*, *S. aureus*, *E. coli*, *K. pneumoniae* and *P. aeruginosa* are the most frequently reported wound-infecting pathogens. Microbial burden prolonged the inflammatory phase of wound healing and produced unpleasant wound exudates and bacterial toxins that subsequently delayed the granulation tissue regeneration.^[14] In wound management therapy, plant-based medicine has gained sufficient attention due to antimicrobial and antioxidant properties.^[4,10] In our experiment, EhME was found to be more active antimicrobial as compared to other extracts with MIC 0.25 mg/ml against *E. coli* and *K. pneumoniae*, both [Table 1]. These findings corroborated with the previous reports of antibacterial activity of *E. hirta*.^[15] Free radical scavenging activity (DPPH, SRSA, FRAP and FCR) results depicted the antioxidant potential of EhME and corroborated with the previous reports.^[16]

Among the different phases of wound repair process, the proliferation phase involves formation of granulation tissue, collagen production/maturation and re-epithelialization. Proliferation phase is initiated by macrophages and actively progressed by fibroblast cells.^[17] The *in vitro* fibroblast proliferation assay indicated the toxic effect of EhPE and EhCE [Figure 2a]. On the other hand, the biphasic proliferation response of EhME and EhWE, might be due to accumulation of growth inhibitory components of the respective crude extract. The EhME and EhWE also effectively antagonized the H_2O_2 -induced fibroblast cell death, in a concentration-dependent manner [Figure 2b], which perhaps due to the antioxidant properties of the respective extracts [Table 2], corroborating with the earlier reports of protective action against H_2O_2 -induced cell damage.^[10] However, EhCE did not show any *in vitro* antioxidant activity (DPPH, SRSA and FRAP), and the protective effect against H_2O_2 -induced oxidative stress could be due to the intracellular antioxidant enzymes (SOD, CAT, etc.) inducing activity. On the other hand, EhPE synergizes the H_2O_2 and decreased the cell population with increasing concentration. From the above *in vitro* antimicrobial, antioxidant and fibroblast cell proliferation studies it was observed that EhME and EhWE possess the higher activity as compared to EhPE and EhCE and showed significant antioxidant and fibroblast proliferation property. However, EhWE showed less potent antimicrobial activity against selected wound-infecting pathogens. Therefore, the methanol extract was considered for *in vivo* wound healing evaluation in Wistar rats in the circular excision model at

2.5% w/w dose (selected after acute skin irritation and toxicity study).

In a wound repair process, wound contraction plays an important role, where the surrounding epithelial tissues rallied by the forces from the granulation tissue. Periodic assessment of wound revealed that EhME treatment showed faster wound contraction rate ($P < 0.05$) than the non-treated and vehicle-treated groups. The wound contraction rate was even faster in EhME than the gentamicin-treated group [Figure 3]. Proliferating fibroblasts in granulation tissue regulate the production, deposition and their subsequent maturation of collagen fibers that impart physical strength to the tissue. Thus, the tissue repair process depends upon the synthesis and depositions of collagen fibers. Hydroxyproline is a basic constituent of collagen structure, contributed to approximately 14% and its content is also an index of collagen synthesis. The hydroxyproline content of granulation tissue in the EhME-treated animal group was higher ($P < 0.05$) as compared to other treated groups including gentamicin sulfate. Histopathological examination on 7 days treatment showed the abundant macrophage and fibroblast infiltration, and 15 days treatment showed profuse fibroblast with mature collagen bundles [Figure 4]. The density of fibroblasts in the matured dermis was higher in the EhME-treated group in comparison to gentamicin and other control groups. The *in vivo* experimental findings of collagen production/maturation, re-epithelialization and wound contraction are the attributes of proliferation phase of wound healing. The proliferative phase is a crucial phase of wound physiology progressed by macrophages and fibroblast. Proliferation phase cascade is controlled and guided by several growth factors such as transforming growth factor- β (TGF- β), basic fibroblast growth factor (bFGF), platelet derive growth factor (PDGF) released by the platelets, macrophages and T lymphocytes.^[17] Various secreted chemotactic molecules increased the infiltration of macrophage and fibroblasts. Released TGF- β bound to the extracellular fibroblast TGF- β receptors and initiated the TGF- β -Smad-mediated collagen production.^[18] On the other hand, bFGF promotes the neovascularization and increases the oxygen content of the granulation tissue to facilitate the collagen production and maturation. The granulation fibroblasts have more affinity for *COL3A1*, among all other collagen genes.^[17] Smad family proteins (TGF- β type I receptor kinases substrate) transduced the receptor signals to a specific target gene to fibroblast nucleus. A complex interplay of Smad-2, -3, -4 and -7 regulates the synthesis of collagen in granulation tissue.^[18,19] The mechanism of collagen production through the Smad-mediated signaling pathway in the granulation fibroblast has been explored earlier^[11,17] and confirmed with our results of up-regulated expression of signal transducer proteins (Smad-2, -3 and -4)

and down regulation of the inhibitory protein (Smad-7) analyzed by western blot [Figure 5]. An ideal wound healing remedy should affect at least two different phases of the wound repair process to substantiate the scientific support. In this regard, our results indicated that *E. hirta* methanol extract possess antimicrobial, antioxidant and fibroblast proliferating activities with collagen production and enhances the level of various proteins and growth factors in wound granulation tissue.

CONCLUSION

E. hirta possess antimicrobial and antioxidant property, increases the fibroblast proliferation and alters the expression of bFGF, *COL3A1* and Smad family proteins during wound repair process in granulation tissue, rationalizing the traditional use of *E. hirta* in wound healing.

ACKNOWLEDGEMENT

Financial support to A.U. in the form of Research Fellowship by DRDO, Ministry of Defence, Government of India, is gratefully acknowledged. Authors are also thankful to Defence Research Laboratory, Tezpur, Assam, (India) and Birla Institute of Technology, Mesra, Ranchi, (India) for providing necessary support for carrying out the research work.

REFERENCES

1. Sandeep BP, Nilofar SN, Chandrakant SM. Review on phytochemistry and pharmacological aspects of Euphorbia hirta LINN. Asian J Pharm Res Healthcare 2009;1:113-33.
2. Mei FS, Jong YC. Potentail application of Euphorbia hirta in pharmacology, In: Omboon V, Suleiman MO, editors. Drug Discovery Research in Pharmacognosy. In Tech, Rijeka: Croatia; 2012. p. 165-80.
3. Yoshida T, Namba O, Chen L, Okuda T. Tannins related polyphenols of Euphorbiaceous plants. V. Euphorbins C, an equilibrated dimeric dehydroellagitannins having a new tetrameric galloyl group. Chem Pharm Bull 1990;38:86-93.
4. Kumar B, Vijayakumar M, Govindarajan R, Pushpangadan P. Ethnopharmacological approaches to wound healing-Exploring medicinal plants of India. J Ethnopharmacol 2007;114:103-13.
5. Thakur R, Jain N, Pathak R, Sandhu SS. Practices in wound healing studies of plants. Evid Based Complement Alternat Med 2011;2011:438056.
6. Hayouni EA, Miled K, Boubaker S, Bellasfar Z, Abedrabba M, Iwaski H, *et al.* Hydroalcoholic extract based ointment from Punica granatum L. peels with enhanced *in vivo* healing potential on dermal wounds. Phytomedicine 2011;18:976-84.
7. Brighente IM, Dias M, Verdi LG, Pizzolatti MG. Antioxidant activity and total phenolic content of some Brazilian species. Pharm Biol 2007;45:156-61.
8. Suntar I, Akkol EK, Senol FS, Keles H, Orhan IE. Investigating wound healing, tyrosinase inhibitory and antioxidant activities of the ethanol extracts of Salvia cryptantha and Salvia cyanescens using *in vivo* and *in vitro* experimental models. J Ethnopharmacol 2011;135:71-7.
9. Wang XH, Dai JT. A comparative study on antioxidant activity of

- water and ethanol extracts of ten Chinese herbs. *J Med Plants Res* 2012;6:2210-5.
10. Adetutu A, Morgan WA, Corcoran O. Antibacterial, antioxidant and fibroblast growth stimulation activity of crude extracts of *Bridelia ferruginea* leaf, a wound-healing plant of Nigeria. *J Ethnopharmacol* 2011;133:116-9.
 11. Upadhyay A, Chattopadhyay P, Goyary D, Mazumder PM, Veer V. *Eleutherine indica* L. accelerates *in vivo* cutaneous wound healing by stimulating Smad-mediated collagen production. *J Ethnopharmacol* 2013;146:490-4.
 12. Khandelwal KR. *Practical Pharmacognosy*. Mumbai, India: Nirali Prakashan; 2008.
 13. Houghton PJ, Hylands PJ, Mensah AY, Hensel A, Deters AM. *In vitro* tests and ethnopharmacological investigations: Wound healing as an example. *J Ethnopharmacol* 2005;100:100-7.
 14. Bowler PG, Duerden BI, Armstrong DG. Wound microbiology and associated approaches to wound management. *Clin Microbiol Rev* 2001;14:2244-69.
 15. Abubakar EM. Antibacterial activity of crude extracts of *Euphorbia hirta* against some bacteria associated with enteric infections. *J Med Plants Res* 2009;3:498-505.
 16. Basma AA, Zakaria Z, Latha LY, Sasidharan S. Antioxidant activity and phytochemical screening of the methanol extracts of *Euphorbia hirta* L. *Asian Pac J Trop Med* 2011;4:386-90.
 17. Kondo T, Ishida Y. Molecular pathology of wound healing. *Forensic Sci Int* 2010;4:203:93-8.
 18. Massague J, Gomis RR. The logic of TGF- β signaling. *FEBS Lett* 2006;580:2811-20.
 19. Schiller M, Javelaud D, Mauviel A. TGF- β -induced SMAD signaling and gene regulation: Consequences for extracellular matrix remodeling and wound healing. *J Dermatol* 2004;35:83-92.

Cite this article as: Upadhyay A, Chattopadhyay P, Goyary D, Mazumder PM, Veer V. *Euphorbia hirta* accelerates fibroblast proliferation and Smad-mediated collagen production in rat excision wound. *Phcog Mag* 2014;10:534-42.

Source of Support: Nil, **Conflict of Interest:** None declared.